

## Egyptian Dermatology Online Journal

Volume 2 Number 1

### **Microscopic study of the normal skin in cases of mycosis fungoides**

**M. El Darouti, S. Marzook, M. Bosseila, O. Abu Zeid, O. El-Safouri, A. Zayed, A. El-Ramly**

**Egyptian Dermatology Online Journal 2 (1): 6, June, 2006**

[mohammed\\_eldarouti@yahoo.com](mailto:mohammed_eldarouti@yahoo.com)

Dermatology Department, Faculty of Medicine, Cairo University; Egypt.

**Accepted for publication in: March, 2006.**

---

### **Abstract**

#### **Background:**

During therapy of mycosis fungoides (MF) patients at our dermatology department, "Kasr El-Aini" hospital, follow up biopsies are routinely taken every 2 months. It was noticed that lesions of MF might become clinically normal during treatment, yet, still show microscopical evidence of MF. This finding raised the possibility that clinically normal skin in MF could be microscopically involved.

#### **Aim:**

The aim of our study was to evaluate the degree of histopathological involvement of normally looking skin in MF patients.

#### **Patients and Methods:**

Thirty patients with stage IB were biopsied from their normal skin. Two biopsies were taken, one proximal (2 cm) and the other was distal (> 5cm) from any visible lesion. Ten normal controls were included in the study. All specimens were stained with H&E and examined microscopically. The microscopical diagnosis was confirmed by immunophenotyping.

#### **Results:**

Epidermotropism was detected in 21 (70%) of proximal skin biopsies and 14 (47%) of distal skin biopsies, whereas no biopsy from the control

group showed epidermotropism. All proximal skin biopsies showed dermal infiltrate and 90% of the biopsies from distal normal skin showed dermal infiltrate (Mostly superficial perivascular). Conclusion: Normal skin in MF patients could be affected microscopically and this may raised questions regarding the credibility of the current staging classification of MF, and may necessitate taking biopsies from normal skin before starting topical treatment. During MF treatment, biopsies from cured lesions are required before starting withdrawal.

## Introduction

Mycosis fungoides represents the commonest form of cutaneous T-cell lymphoma subsets, which is a monoclonal neoplastic disorder of T-helper cell-lineage [1]. The molecular mechanism for the migration of neoplastic T-lymphocytes into the epidermis is complex and multifactorial [2]

Several clinicopathologic variants of MF have been delineated including erythrodermic MF, hypopigmented MF, purpuric MF, syringotropic MF, follicular MF, vesicular MF, granulomatous MF and granulomatous slack skin [3].

One of the most recently described variants of MF is invisible MF, which was first reported by Pujol and associates in 2000 [4] in which pathological evidence of mycosis fungoides (epidermotropism, Pautrier's microabscesses and atypical lymphocytes) was found on histopathological examination of normally looking skin of a 76 years old woman presenting only by persisting pruritus. This diagnosis was confirmed by immunophenotyping and gene rearrangement analysis. Two other cases of invisible MF were reported later on [5&6].

The histological appearance of clinically uninvolved skin in MF patients with patch stage disease was evaluated in an earlier study made by Bergman and associates (1995) [7], and epidermotropism was found in 50% of biopsies and mononuclear cell infiltrate around the blood vessels in the papillary dermis in 33% of biopsies. This would mean, in addition to the previous findings of invisible MF, that clinically normal skin in MF could be microscopically involved.

During therapy of MF patients at our dermatology department, "Kasr El-Aini" hospital, follow-up biopsies are routinely taken every 2 months. Biopsies are always taken from areas close to the site of the original biopsy in order to ensure more accurate evaluation of the histopathological progression of the same MF lesion during treatment. It was noticed that lesions of mycosis fungoides might become clinically normal during treatment, yet, still show microscopical evidence of MF. This finding raised the possibility that clinically normal skin in MF could be microscopically involved.

Based on our findings of the presence of histopathological evidence of MF in the MF lesions that have been rendered clinically normal by treatment, and based on the previous recent reports of invisible MF as well as the reports of microscopical affection of normal skin in MF, we decided to make a histopathological study of normal skin in our MF patients.

## **Patients and Methods**

This study included 30 patients and 10 healthy volunteers as controls. The patients were selected from the outpatient dermatology clinic of Cairo University Hospital (Kasr El-Aini) over a period of 24 months. The patients included 7 females and 23 males with mycosis fungoides, stage IB, and their ages ranged from 9 to 69 years. The MF lesions included patches (9 patients) patches and plaques (13 patients) and plaques (8 patients).

Three skin biopsies were taken from each patient (5 mm in diameter) before starting treatment, one from the mycosis fungoides lesions and the other two from normal skin. One of the normal skin biopsies was taken 2 cm away from the nearest lesion (proximal), and the other was taken from areas more than 5 cm away from the nearest lesion (distal). The biopsies were paraffin fixed, stained with hematoxylin and eosin, and then examined by light microscopy.

All biopsy specimens stained positively with the following markers: CD3 and CD4. CD7 was lost in 27 specimens and CD8 was focally positive in 10 cases.

Controls: Ten healthy volunteers served as controls. They included 4 females and 6 males and their ages ranged from 15-31 years. A skin biopsy was taken from the normal skin of each individual in the control group, and the biopsies were subjected to the same processes mentioned above.

Data management and statistical analysis: Statistical software package SPSS 9.0 was used in the analysis. Frequency and percent were calculated for qualitative values, while mean and standard deviation were calculated for quantitative values. Chi square test ( $\chi^2$ ) was performed to compare qualitative values and estimate the level of significance. P value less than 0.05\* was considered statistically significant.

## **Results**

All patients included in the study had MF stage 1B. The clinical diagnosis in each case was substantiated by the histopathological findings of epidermotropism as well as superficial perivascular dermal infiltrate of

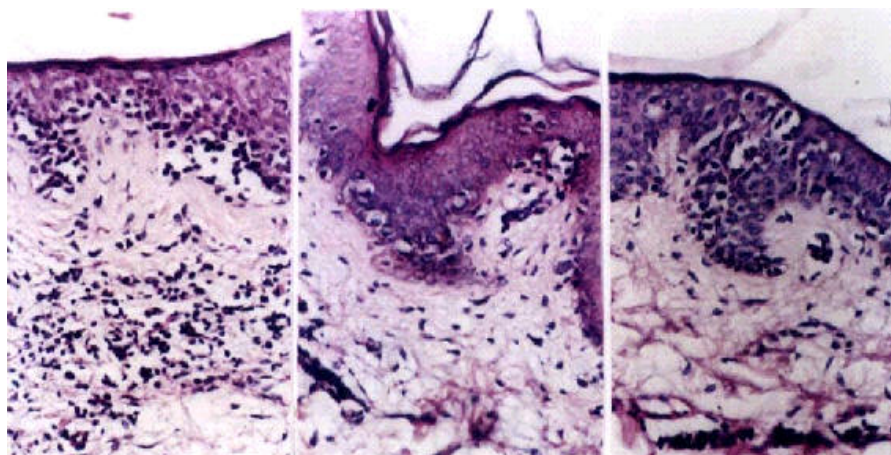
variable intensity (table 2). Immunophenotyping showed universal positivity with CD3 and CD4 staining. The majority of cells (50%-70%) were CD3 and CD4 positive. Only 30% of the CD3 positive cells reacted with antiCD7 and in about 40% of the cases there was focal positivity with anti CD8.

Epidermotropism was found in 21 biopsies (70%) of proximal normal skin biopsies, 53% of them had few lymphocytes in the epidermis and 17% had numerous lymphocytes in the epidermis. Whereas in distal normal skin biopsies only 14 patients (47%) showed epidermotropism, 40% of those biopsies showed few lymphocytes and 7% showed numerous lymphocytes in the epidermis ([Fig 1](#)). There was no evidence of epidermotropism in any of the biopsies of the control group ([table 1](#)), and these differences were statistically significant, p values being 0.001 and 0.007, respectively.

All proximal skin biopsies showed dermal infiltrate. Most of them, 26 patients (86.67%), showed superficial perivascular lymphocytic infiltrate, whereas 3 biopsies (10%) showed also mid-dermal infiltrate and 1 biopsy (3.33%) showed deep dermal infiltrate in addition to the superficial perivascular infiltrate. As regards distal skin biopsies, a total of 27 patients (90%) showed dermal infiltrate. Most of them, 25 patients (83.33%), showed superficial perivascular lymphocytic infiltrate, and 2 patients (6.67%) showed also mid-dermal infiltrate in addition to the superficial perivascular infiltrate. In the control group 4 candidates only (40%) had superficial perivascular dermal infiltrate ([table 2](#)), and these differences were statistically significant, p values being 0.001 and 0.004, respectively.

Regarding the density of dermal infiltrate most of the biopsies from proximal skin (63%) showed sparse dermal infiltrate, and 33% of biopsies showed moderate infiltrate, and only 3% had dense infiltrate, whereas in distal skin more biopsies (83%) showed sparse dermal infiltrate and 7% showed moderate infiltrate, but none showed dense dermal infiltrate ([table 3](#)).

**Fig 1:** Lesional, proximal and distal normal skin biopsies of a patient with stage IB MF, H&E, x 400.



Lesional biopsy	Proximal normal skin biopsy	Distal normal skin biopsy
<p>Mildly hyperplastic epidermis. Numerous intraepidermal lymphocytes arranged singly and in small clusters among the basal cells. Clear haloes are seen around the epidermotropic lymphocytes.</p> <p>Moderately dense superficial perivascular lymphocytic infiltrate.</p>	<p>Mildly hyperplastic epidermis. Intraepidermal lymphocytes arranged singly and in small clusters among the basal cells, in a focal distribution. The epidermotropic cells are surrounded with clear haloes.</p> <p>Sparse superficial perivascular lymphocytic infiltrate.</p>	<p>Mildly hyperplastic epidermis. Few intraepidermal lymphocytes arranged among the basal cells, as well as the upper part of the epidermis. The epidermotropic lymphocytes are arranged in small clusters and are surrounded with clear haloes.</p> <p>Sparse superficial perivascular infiltrate.</p>

**Table (1):** Epidermotropism in proximal and distal normal skin biopsies compared to the control group.

Epidermotropism (proximal sites, n=30)			Epidermotropism (distal sites, n=30)			Epidermotropism (control, n=10)	
n	%	p-value	n	%	p-value	n	%
21	70%	0.001*	14	46.67%	0.007*	0	0%

**Table (2):** Depth of dermal infiltrate in both proximal and distal normal skin biopsies compared to the control group.

Depth of dermal infiltrate

	Number and percentage of patients					
	Proximal (n=30)		Distal (n=30)		Control (n=10)	
	n	%	n	%	n	%
No infiltrate	0	0%	3	10%	6	60%
Sup. perivascular	26	86.67%	25	83.33%	4	40%
Upper dermal	0	0%	0	0%	0	0%
Mid dermal	3	10%	2	6.67%	0	0%
Deep dermal	1	3.33%	0	0%	0	0%
P-value	0.001*		0.004*			

**Table (3):** Comparison between the density of dermal infiltrate in both proximal and distal normal skin biopsies and the control group.

Density of dermal infiltrate

	Number and percentage of skin biopsies					
	Proximal (n=30)		Distal (n=30)		Control (n=10)	
	N	%	n	%	n	%
No infiltrate	0	0%	3	10%	6	60%
Sparse (+) perivascular	19	63.33%	25	83.33%	4	40%
Moderate (++)	10	33.33%	2	6.67%	0	0%
Dense (+++)	1	3.33%	0	0%	0	0%
P-value	0.001*		0.004*			

## Discussion

The aim of our study was to assess the degree of histopathological involvement of normally looking skin in patients with mycosis fungoides. Invisible mycosis fungoides as a variant of MF was only recently described [4], in which pathological evidence of MF was found in biopsies taken from clinically normal skin. Later on, two other cases of invisible MF were described [5&6]. These three cases share many striking points; generalized pruritus of long duration in an elderly patient, no skin lesions but only small excoriations, good general status, and histological and immunohistochemical patterns typical of MF. These observations suggest that more attention should be given to elderly patients who complain of long-standing pruritus without any evident cause. Skin biopsies should be taken from these patients to exclude MF [6]. They also point to the possibility that normally looking skin in MF could be microscopically involved.

The first one to study normally looking skin in MF patients was Braverman and colleagues (1987), who studied skin biopsies from 9 clinically cleared MF patients after treatment. They found a few individual "MF cells" within the epidermis, in the absence of inflammatory infiltrate in the dermis. The authors stated that they have never seen these changes in the normally appearing skin of healthy individuals or patients with a variety of common skin diseases.

Another study was conducted later on by Bergman and associates (1995)[7], evaluating the histologic appearance of the clinically uninvolved skin in plaque stage MF patients. The study included 18 untreated patients of only plaque stage disease and 23 normal, healthy controls. Two biopsies were taken from the clinically uninvolved skin, one was 1 cm (near) and the other was < or = 10 cm (far) from the MF lesions.

The most common histologic finding, which was observed in six (33%) biopsies of near skin and four (22%) biopsies of far skin, consisted of mononuclear cell infiltrate around the blood vessels in the papillary dermis, with extension of some of these cells into the overlying epidermis. More diffuse epidermotropic mononuclear cell infiltrates were seen in 3 additional biopsies (17%) of near skin. They concluded that these histological findings might represent an earlier stage of the disease and clinically undetectable involvement of the normal looking skin in MF patients.

Our study was different from that of Bergman and associates'(1995) in the fact that it included more patients (30 patients compared to only 18 patients), and that the proximal skin biopsies were taken 2 cm away from any visible lesion and the distal biopsies were taken more than 5 cm away from any visible lesion, whereas in Bergman and associates'(1995) study the biopsies were taken 1cm and 10 or more cms, respectively. The percentage of biopsies showing epidermotropism involved was more in our study (70% and 46.67%) in proximal and distal skin biopsies respectively compared to (50% and 22%) in Bergman and associates'(1995) study.

None of the control group in our study showed epidermotropism, whereas in Bergman and associates'(1995)[7] study, 1 subject of the control group showed epidermotropism.

In the present study the percentage of biopsies showing dermal infiltrate was (100 % and 90%) in proximal and distal normal skin biopsies respectively compared to (33% and 22%) in Bergman and associates' (1995) study. However, our results were consistent with their results in the fact that the most common histologic finding in all skin biopsies was the presence of superficial perivascular infiltrate which was observed more in proximal normal skin biopsies, and the second significant finding observed in both studies was the presence of epidermotropism.

Mycosis fungoides can be considered a systemic disease from the onset, as 50% of patients with early disease have clones of T-cells in their blood [5]. Based on this fact it is not surprising to find T-cells in biopsies from clinically uninvolved skin in MF and our finding is a further evidence that MF is a systemic disease, or at least it is more wide spread than it looks.

There are three important implications raised by our findings. First, the current staging of MF should be modified and expanded in a way to incorporate the fact that clinically normal skin in MF could be microscopically involved. For example, a patient having patches and plaques of MF spanning < 10% of the body and classified as T1 according to the current TNM staging system, could in fact have more extensive microscopic affection of the clinically normal skin.. Accordingly biopsies from normal skin should be obtained before staging. By doing this a more accurate estimation of the extent of MF can be obtained.

Second, topical treatment of MF should be reconsidered. Such therapeutic approach may be adopted in cases of monolesional MF, in stage IA MF and in MF in children. The possible affection of normal skin (proved in our study as well as in other studies)[4-7] indicates that topical treatment of MF should not be attempted except after taking biopsies from normally looking skin to exclude the possibility of a more widespread microscopic skin affection, warranting systemic treatment instead of topical. It should be reemphasized that taking biopsies from normal skin should not be attempted unless the diagnosis of MF has been established in the clinically presumed lesions. If the biopsy from normally looking skin showed evidence of MF, unnecessary delay of systemic treatment would be avoided.

Finally during treatment of MF, follow up biopsies are required, preferably from the same site of the original biopsy, in order to verify the microscopic status of the clinically cured MF lesions before starting treatment withdrawal.

It can be assumed that microscopic affection of the the clinically normal skin in MF could adversely affect the prognosis, particularly when the normal skin involvement is not considered at the time of staging and later during treatment. To verify this assumption we are currently evaluating the effect of

the same treatment on two groups of MF patients presenting with the same stage. In one group patients show microscopic evidence of MF in their apparently normal skin, whereas in the other group there is no microscopic involvement of the normally looking skin.

## References

1. LeBoit, P.E. and McCalmont, T. (1997): Cutaneous lymphoma and leukemia. In *Lever's Histopathology of the skin* (eighth edition). Edited by Elder, D.; Elenitsas, R.; Jaworsky, C. and Johnson, Jr.,B., published by Lippincott-Raven, Vol. III, chapter 32, page 805.
2. Siegel, R.S.; Pandolfino, T.; Guitart, J.; Rosen, S. and Kuzel, T.M. (2000): Primary Cutaneous T-Cell Lymphoma: Review and Current Concepts. *J. Clin. Oncol*; 18: 2908-25.
3. Heald, P.W. and Edelson, R.L. (1999): Cutaneous T-cell Lymphomas. In: Fitzpatrick TB, Eisen AZ, Wolf K; et al. (eds): *Dermatology in general medicine*, (ed 5). New York, NY, McGraw-Hill, chapter 108, page 1227.
4. Pujol, R.M.; Gallardo, F.; Llistosella, E.; Blanco, A.; Bernado, L.; Bordes, R.; Nomdedeu, J. and Servitje, O. (2000): Invisible mycosis fungoides: a diagnostic challenge. *J. Am. Acad. Dermatol.*; 42: 324-8.
5. Hwong, H.; Nichols, T. and Duvic, M. (2001): "Invisible" mycosis fungoides. *J. Am. Acad. Dermatol.*; 45: 318.
6. Dereure, O. and Guilhou, J. (2001): Invisible mycosis fungoides: A new case. *J. Am. Acad. Dermatol.*; 45: 318-9.
7. Bergman, R.; Cohen, A.; Harth, Y.; Nahhas, L.; Shemer, A.; Ramon, J.; Lichtig, C. and Friedmann-Birnbaum R. (1995): Histopathologic findings in the clinically uninvolved skin of patients with mycosis fungoides. *Am. J. Dermatopathol.*; 17: 452-6.
8. Braverman, I.M.; Klein, S. and Grant, A. (1987): Electron microscopic and immunolabeling studies of the lesional and normal skin of patients with mycosis fungoides treated by total body electron beam irradiation. *J. Am. Acad. Dermatol.*; 16: 61-74.