

Egyptian Dermatology Online Journal

Volume 7 Number 2

Sweet's syndrome reveals a tuberculosis lymph node

Khammassi Naziha¹, Ben Sassi Maha², Mohsen Dorsaf¹, Abdelhedi Haykel¹, Cherif Ouahida¹.

¹ Department of Internal Medicine, Razi Hospital, 2010- Manouba, Tunisia.

² Department of Dermatology, Ben Arous Hospital, Tunisia.

Egyptian Dermatology Online Journal 7 (2):6

Corresponding author: Dr Khammassi N.

E-Mail: naziha.khammassi@rns.tn

Submitted: May 25, 2011

Accepted: July 10, 2011

Abstract

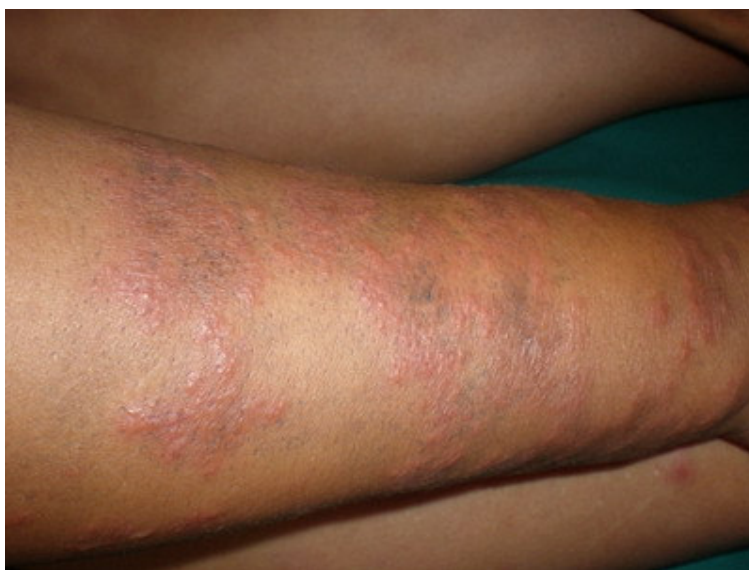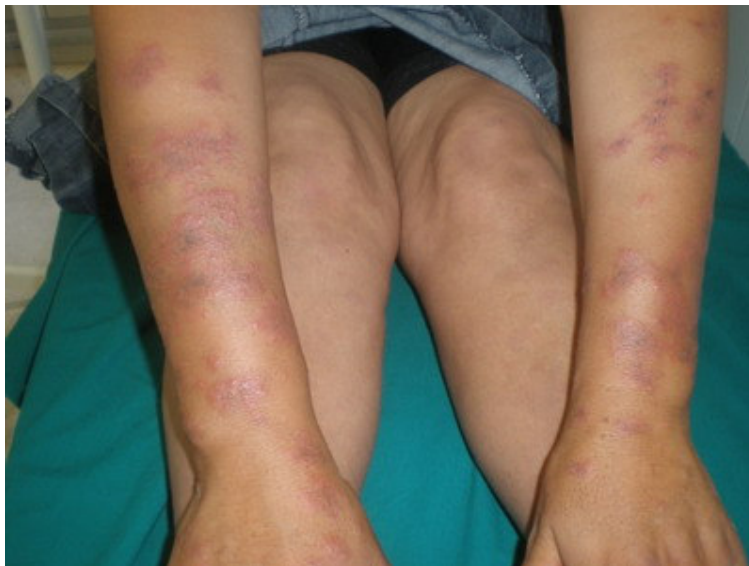Acute febrile neutrophilic dermatosis or Sweet's syndrome is the most common neutrophilic dermatoses, a nosological framework of a widening spectrum of anatomical and clinical entities and a new set of atypical, unusual or complex forms. This syndrome is often associated with hematologic malignancies. Other non-neoplastic associations have been, however, described. We report a case of a patient in whom the onset of Sweet's syndrome has led to the diagnosis of lymph node tuberculosis. The occurrence of Sweet's syndrome must perform a complete assessment including a search of tuberculosis.

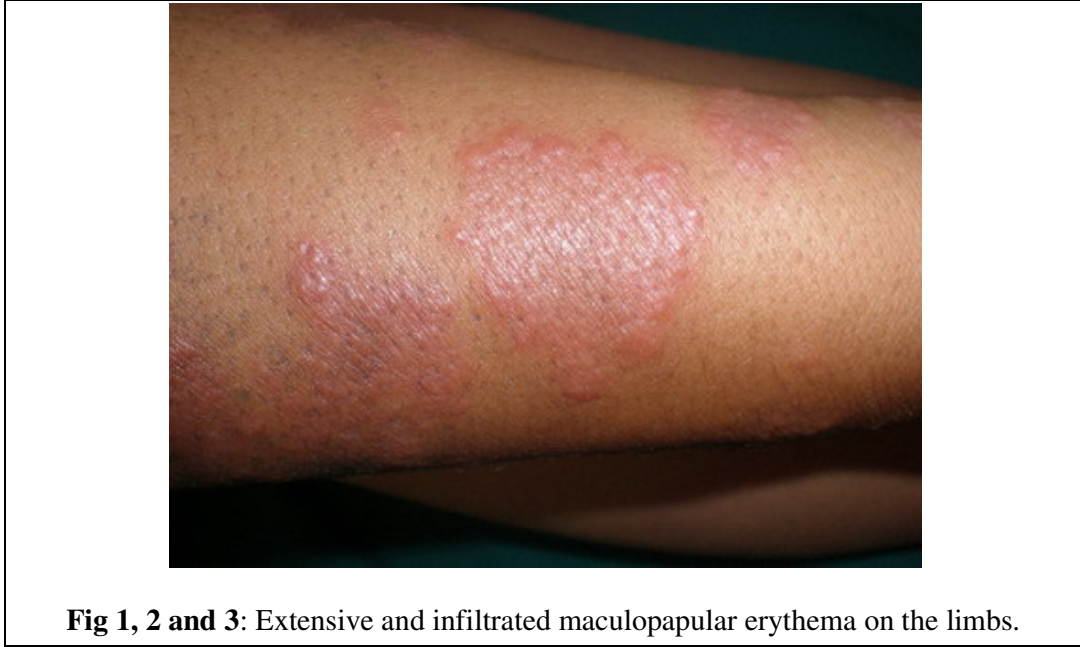Introduction

Sweet's syndrome is characterized by pyrexia, elevated neutrophil count, tender erythematous skin lesions (papules, nodules and plaques) and a diffuse infiltrate consisting predominantly of mature neutrophils typically located in the upper dermis. The classical form is preceded by an upper respiratory tract infection or gastrointestinal tract infection. The diagnostic criteria are clinical, biochemical and histological. This syndrome is often associated with hematologic malignancies and even infections such as tuberculosis [1]. We report a case of Sweet's syndrome revealing lymph node tuberculosis.

Case Report

A 32-year-old woman, without previous history of drug administration, was admitted to the hospital because of a-week history of dermal erythematous plaques on the limbs and chest (**Fig 1, 2, 3**) associated to arthralgias.





Physical examination revealed conjunctival hyperemia, fever 38 ° C and right cervical sub-maxillary angle lymphadenopathy, fixed at 3 cm of diameter. The ultrasound examination showed cervical lymph nodes under the right digastric muscle. Chest x-ray was normal.

The lymph node biopsy has been in favor of tuberculosis.

There was a high sedimentation rate to 85 at the first hour, white blood cells to 6300 elements per mm³. The remaining balance was normal.

On histologic examination (**Fig4**), the dermis is edematous, has an inflammatory infiltrate, made of numerous polymorphonuclear neutrophils with few evidence of leucocytoclastic vasculitis, and associated with mononuclear cells. It has not been observed histological signs of malignancy. The diagnosis of Sweet syndrome associated with lymph node tuberculosis was established. The patient was treated with colchicine at a dose of 1mg/kg/jour. All skin lesions resolved rapidly. An anti-tuberculosis treatment was also instituted.

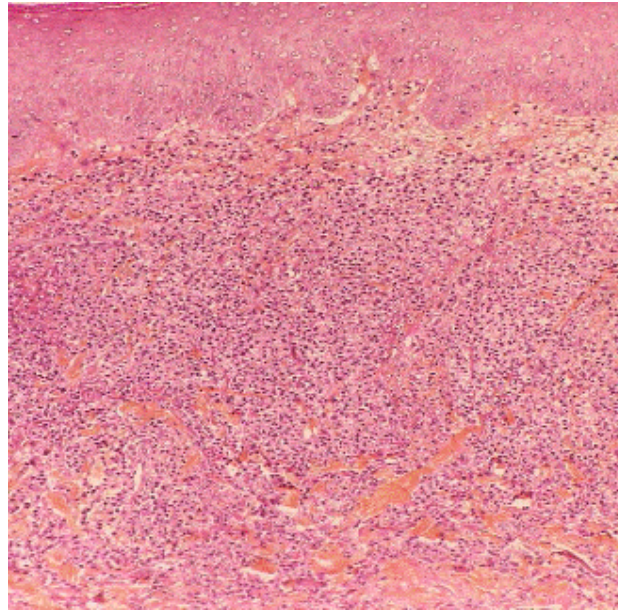


Fig 4: Inflammatory infiltrate of the dermis, made of numerous polymorphonuclear neutrophils without vasculitis

Discussion

Described in 1964 by Sweet, this syndrome is characterized by the sudden influx of neutrophils into the dermis in the absence of any infection [2]. The same infiltration by neutrophils may occur in deep organs [3]. It is usually observed in adults in the fourth decade and more often in women than in men [4]. Childhood cases are rare. In about 75% of cases the rash is preceded by signs of rhinitis, pharyngitis, cough, malaise, muscle pain or digestive problems, all suggestive of a viral infection. The skin lesions then appear suddenly are in the form of erythematous papules and nodules. Plaques are very limited, painful, with raised hummocky surface extending centrifugally, leaving a central depression. These plates may have a vesicular or pustular surface. They are limited or sometimes even multiple and disseminated. The lesions are first asymmetric in distribution then they become symmetrical. They sit preferentially in the face, neck, the posterior surface of the forearms, backs of hands and fingers, lower limbs and rarely on the back [5].

The diagnosis usually poses few problems. The clinical appearance of lesions, their distribution and massive infiltration of the dermis by neutrophils without vasculitis are the major criteria of diagnosis [6].

In our patient, the absence of leukocytosis and the presence of cervical lymph nodes, led us to push the exploration that confirmed the diagnosis of tuberculosis. Our observation stresses the importance of a comprehensive assessment (chest radiograph, Mantoux test and research of Koch bacillus) before any suspicion of tuberculosis, especially in endemic countries like ours.

SS is most often idiopathic, but sometimes associated with various pathological conditions including malignancies. It is sometimes associated with visceral cancers such as testicular carcinoma and ovarian carcinoma. It has also been described in association with some infectious diseases such as tuberculosis, toxoplasmosis, salmonellosis, or infection with HIV [7].

In the series of Boudghene-Stambouli and al [8], the SS was significantly associated with chronic lymphocytic leukemia complicated by tuberculous ascites, lymph node tuberculosis and ulcer perianal tuberculosis.

The pathogenesis of SS remains unknown. Some authors suggest that lesions may be secondary to a hypersensitivity reaction to an allergen [9]. Interleukin-1 might play a role as mediator of inflammation [10]. The GCSF (granulocyte colony stimulating factor), growth of neutrophils, is certainly also involved, either by increasing its synthesis or by the existence of hypersensitivity to this cytokine [11]. It could finally be a genetic predisposition. Moreover SS seems more common in Japan, and HLA-Bw54 has been described as a risk factor [12].

Treatment is symptomatic. Efficiency of systemic corticosteroids is spectacular [5].

If SS was associated to tuberculosis, other therapies such as colchicine may be used [8,13].

Conclusion

Sweet's syndrome is not uncommon. It is most often idiopathic, but sometimes associated with other diseases, especially infection. The association with tuberculosis should be noted. Corticosteroids should be handled with great caution. Treatment by colchicine must be useful, because of its efficiency.

References

1. Von den Driesch P. Sweet's syndrome (acute febrile neutrophilic dermatosis). *J Am Acad Dermatol* 1994;31:535-56.
2. Sweet RD. An acute febrile neutrophilic dermatosis. *Br J Dermatol*, 1964; 76: 349-356.
3. WALLACH D. Les dermatoses neutrophiliques. *Presse Méd.* 1991; 20: 105-107.
4. Sweet RD. Acute febrile neutrophilic dermatosis. *Br J Dermatol*, 1979; 100: 93-9.
5. Samon-Ehr V, Estève E, Serpier H et al. Dermatose neutrophilique aigue fébrile pustuleuse et bulleuse révélant une leucémie aigue myéloblastique. *Rev Méd Interne* 1995; 16: 347-350.
6. Su WPD, Liu HNH. Diagnostic criteria for Sweet's syndrome. *Cutis* 1986; 37: 167-74.
7. Von den Driesch P. Sweet's syndrome (acute febrile neutrophilic dermatosis). *J Am*

Acad Dermatosis). *J Am Acad Dermatol* 1994; 31: 535-56.

8. Boudghene -Stambouli O, Merad-Boudia A. Dermatose aigue febrile neutrophilique aspect clinique, évolutif et thérapeutique. A propos de 55 observations. *Les nouvelles dermatologiques* 1996; 15: 702-706.

9. Petrozzi JW, Warthan TL. Sweet's syndrome: unique local response to streptococcal antigen. *Cutis* 1976; 17: 267-72.

10. Going JJ. Is the pathogenesis of Sweet's syndrome mediated by interleukin-1? *Br J Dermatol* 1987; 116: 282-3.

11. Park JW, Mehrotra B, Barnett BO, Baron AD, Venook AP. The Sweet syndrome during therapy with granulocyte colony-stimulating factor. *Ann Intern Med* 1992; 116: 996-8.

12. Mizoguchi M, Matsuki K, Mochizuki M et al. Human leukocyte antigen in Sweet's syndrome and its relationship to Behçet's disease. *Arch Dermatol* 1988; 124: 1069-73.

13. Suehisa S, Tagami H, Inoue F, Matsumoto K, Yoshikuni K. Colchicine in the treatment of acute febrile neutrophilic dermatosis (Sweet's syndrome). *Br J Dermatol* 1983; 108: 99-101.